

Cutaneous Vasculopathy Associated with Levamisole-adulterated Cocaine

Huy Tran, MD, PhD; Debbie Tan, MD; and Thomas P. Marnejon, DO

Word count, text: 1601 text, 175 abstract, 2 figures, 0 tables

Corresponding author:

Thomas Marnejon, DO
Department of Medicine
St. Elizabeth Health Center
1044 Belmont Avenue
Youngstown, OH 44501
Tel: (330) 480-3344
Fax: (330) 480-3777
Email: thomas_marnejon@hmis.org

Received: March 6, 2012
Revised: May 10, 2012
Accepted: May 16, 2012

doi:10.3121/cmr.2012.1085

Conflict of interest statement: Huy Tran, MD, PhD, Debbie Tan, MD and Thomas Marnejon, DO disclose no conflicts of interest

Disclosures: All authors participated in authorship. No funding to disclose.

ABSTRACT

We report a case of cutaneous vasculopathy associated with the use of levamisole – adulterated cocaine. This recently described clinical entity is characterized by a purpuric rash with a predilection for the ears, leukopenia and ANCA positivity. It is estimated that more than 70% of the current US cocaine supply is contaminated with levamisole. Levamisole is a widely available, inexpensive white powder used as a “cutting agent” in cocaine to expand volume and increase profits. It may also increase the euphoric and stimulatory effects of cocaine by increasing brain dopamine levels and producing amphetamine-like metabolites. Our patient exhibited a characteristic rash with involvement of the ears, leukopenia, and cocaine metabolites detected in serum and urine; the presence of levamisole was confirmed in the urine utilizing gas chromatography – mass spectrometry. ANCA positivity was also present. Punch biopsy of the skin demonstrated vascular thrombosis and necrosis without true vasculitis. We review the literature reported cases of cocaine - levamisole cutaneous vasculopathy syndrome, highlight the salient immunologic abnormalities, and contrast the features of this entity with idiopathic systemic vasculitis.

Keywords: Levamisole; Cocaine; Cocaine-levamisole cutaneous vasculopathy; ANCA

CASE PRESENTATION

CASE 1

A 45-year-old Caucasian man presented to our emergency department with a rash on his ears and legs of one week duration. The lesions on his ears were described as painful. He also had arthralgias of his hands, but denied fever, chills, sore throat and cough. He also denied epistaxis, hemoptysis, hematemesis, melena, hematuria and Raynaud's phenomenon. History was significant for chronic back pain, chronic hepatitis C infection, and intermittent cocaine use. There were no known drug allergies; his only medication was over the counter ibuprofen for pain.

On physical exam, the patient was afebrile. Exam of the skin revealed a violaceous, non-blanching rash in a retiform pattern with areas of necrosis located on the helix and earlobes bilaterally (Figure 1a) and both knees (Figure 1b). There were no mucosal lesions, lymphadenopathy, or hepatosplenomegaly. Laboratory testing showed a white blood cell (WBC) count of 3,200 per mm^3 (normal range of 4,500 to 11,500 per mm^3). The platelet count was 148,000 per mm^3 . Hemoglobin, coagulation studies, urinalysis, basic metabolic panel, renal and hepatic functions were normal. Erythrocyte sedimentation rate and C-reactive protein were normal. Toxicology revealed a positive cocaine metabolite, benzoylecgonine, in urine utilizing gas chromatography – mass spectrometry (GC-MS) (Arup Laboratories, Salt Lake City, UT). Levamisole was also detected in the urine via GC-MS (Toxicology Laboratory, Colorado Department of Public Health and Environment).

Approximately one year prior to the current presentation, the patient was admitted for a similar rash which was present on his ears, elbows, legs and trunk. At that time the rash was described as macular, violaceous and non-blanching, with areas of central necrosis. Tests for rheumatoid factor, cryoglobulin and anti-nuclear antibody (ANA) were negative. C3 and C4 were within normal range (65 mg/dL and 14 mg/dL, respectively). Enzyme linked immunosorbent assay (ELISA) for anti-proteinase 3 anti-neutrophil cytoplasmic antibodies (PR3-ANCA) was positive at 43 AU/ml (normal 0-19 AU/ml). ELISA for anti-myeloperoxidase (MPO-ANCA) was also mildly positive at 22 AU/ml (normal 0-19 AU/ml), which became negative on repeat testing, as skin lesions improved. IgM anti-cardiolipin antibody was 35 MPL U/ml (normal 0-12 MPL/ml). Lupus-like anticoagulant was weakly positive. Testing for Human Immunodeficiency virus, Parvovirus, Cytomegalovirus, and Epstein-Barr virus were all negative. The cocaine metabolite, benzoylecgonine, was detected in urine. A punch biopsy of the lesion over the patient's elbow demonstrated microthrombi with overlying epidermal necrosis (Figure 2a and 2b). The patient was treated with high dose prednisone (1mg/kg/day) for 2 months which was tapered to a dose of 15mg/day. The rash on his trunk and extremities improved while the rash on the earlobes completely resolved. Prednisone was discontinued 5 months prior to this present emergency room encounter. The patient reported cessation of cocaine use during that same time period.

DISCUSSION

The differential diagnosis of retiform purpura, which is characterized by stellate or branching purpuric lesions, is extensive and includes small and medium-sized vessel vasculitis, infectious

and embolic phenomenon, warfarin skin necrosis, disseminated intravascular coagulation, cryoglobulinemia and anti-phospholipid antibody syndrome. In users of cocaine contaminated with levamisole, a cutaneous vasculopathy syndrome has recently emerged and is characterized by a distinctive purpuric rash with a predilection for the ears, ANCA positivity, and leukopenia.¹⁻

3

Levamisole, an antihelminthic with immunomodulatory properties, was previously used for the treatment of autoimmune disorders, pediatric nephritic syndrome and cancer. It was withdrawn from the market in 2000 due to its adverse side effect profile, specifically agranulocytosis. Levamisole is now found as an adulterant in as much as 70%-88% of cocaine in the United States.^{4,5} Levamisole is a widely available, inexpensive white powder which is used as a “cutting agent” in cocaine to expand volume and increase profits. Levamisole may also increase the euphoric and stimulatory effects of cocaine by increasing brain dopamine levels and producing amphetamine-like metabolites.⁶ Cutaneous manifestations associated with levamisole use are varied and include nonspecific eruptions, lichenoid eruptions, fixed drug rash and cutaneous vasculitis.⁷ Lesions may appear suddenly and enlarge rapidly. Purpuric papules, plaques, hemorrhagic bullae and even midline destruction have also been reported.⁷⁻⁹ In the cocaine – levamisole cutaneous vasculopathy syndrome, lesions frequently have a distinctive morphology; they tend to be stellate with a bright erythematous border and necrotic appearing center.^{1,10} One of the most unique features of this syndrome is that the rash has a predilection for the ears which has been documented in many case reports and case series.^{2,3,8,11,12} It is interesting to speculate on the reason why the ears are preferentially involved. It may be due to the fact that the lower temperature of the ear may facilitate the deposition of

immune complexes.⁷ The histopathologic findings of cocaine – levamisole cutaneous vasculopathy syndrome range from leukocytoclastic and thrombotic vasculitis to vascular occlusive disease without true vasculitis.¹ Biopsy features may show necrosis of small and medium-sized vessels of the dermis and subcutis or an occlusive vasculopathy with intravascular fibrin thrombi and epidermal necrosis without vasculitis.^{2, 12}

Detection of levamisole in both serum and urine must be performed using GC-MS or liquid chromatography – tandem mass spectrometry (LC-MS) as it is not detectable by routine toxicologic testing. The half-life of levamisole is approximately 5.6 hours and limited amounts are excreted in the urine which can make detection difficult.¹³ In a recent review of 16 cases of cutaneous vasculitis syndrome secondary to levamisole-adulterated cocaine, Gross et al. noted that only 12.5% of patients tested positive for levamisole.¹ Based upon the characteristic clinical picture and the widespread adulteration of cocaine with levamisole, some authors believe that a positive test for levamisole is not required to make the diagnosis of this syndrome.^{1, 14}

Cocaine – levamisole cutaneous vasculopathy syndrome has unique immunologic abnormalities, the most important of which is ANCA positivity.^{1, 2, 7, 8, 14-16} This can present a significant diagnostic challenge and renders it difficult to distinguish from true idiopathic systemic vasculitis. In cocaine – levamisole vasculopathy patients, high titer ANCAs against multiple antigens, higher incidence of antiphospholipid antibodies, and low titer ANA, are characteristic.¹⁴ Specifically, these patients may have high titer p-ANCA positivity alone^{2, 8} or characteristically, both p-ANCA and c-ANCA, with anti-MPO and anti-PR3 positivity.^{1, 7, 14, 16} In systemic vasculitis, reactivity to anti-PR3 alone is sensitive and specific to Wegener

granulomatosis, whereas reactivity to anti-MPO alone is typically associated with microscopic polyangiitis and Churg-Strauss syndrome. Low titer ANA and antiphospholipid-antibodies have been reported in several cases.^{7, 14, 16, 17} Recently, anti-human neutrophil elastase (HNE), a subset of ANCA, has been reported to distinguish the cocaine-levamisole vasculopathy syndrome from true autoimmune vasculitis.¹⁸

ANCA-associated vasculitis has been linked to various drugs, such as hydralazine, propylthiouracil and minocycline.¹⁹ Immunologic abnormalities found in drug-induced ANCA-associated vasculitis include high titer anti-MPO antibodies or combined positivity of both anti-MPO and anti-PR3, ANA, and anti-cardiolipin antibodies, similar to that observed in cocaine-levamisole cutaneous vasculopathy.¹⁹ Typically, a prolonged exposure to a causative drug is required before the development of drug-induced autoantibody production. Rongioletti et al. documented a mean latency of 24 months of exposure to levamisole prior to the development of circulating antibodies.⁷ ANCA and anti-phospholipid antibodies induced by levamisole exposure normalize within 2 to 14 months after discontinuation of the drug.⁷

The association of levamisole with leukopenia and agranulocytosis in the treatment of autoimmune disorders and cancer has been well documented.²⁰ Similarly, there have been multiple reports of leukopenia and agranulocytosis secondary to the use of cocaine contaminated with levamisole.²¹⁻²⁴ Gross et al. reported that 10 out of 16 patients (63%) with this syndrome had either leukopenia with WBC count less than 4,000 per mm³ or neutropenia with ANC less than 1,500 per mm³.¹ Of note, leukopenia was present in our patient.

Presently, it is unclear why this syndrome develops in certain cocaine users. It has been postulated that the presence of 6-phenyl-2, 3-dihydroimidazo(2,1b)-thiazole, one of the three breakdown products of levamisole, with lymphocyte-stimulating effects, could play a role in pathogenesis.^{14, 25} An association between levamisole-induced agranulocytosis and HLA-B27 positivity has also been documented.²⁶

Currently, there is no consensus on the treatment of cocaine – levamisole cutaneous vasculopathy syndrome. It is unclear whether steroids offer any benefit, and their use must be balanced against side effects.¹ The role of other immunosuppressants is also controversial, especially when patients present with leukopenia or agranulocytosis.¹⁶ As with other drug-induced vasculitides, resolution can be hastened by withdrawing the offending drug. Recurrent skin lesions do occur when patients are re-challenged with levamisole-adulterated cocaine.¹⁷ Recurrent lesions on re-challenge was noted in our patient; purpuric lesions on the earlobes and knees recurred after re-using cocaine (Figure 1).

SUMMARY

We present a case of cutaneous vasculopathy associated with levamisole-adulterated cocaine as manifested by a stellate purpuric rash with involvement of the ears and leukopenia. Levamisole was detected in the urine and ANCA positivity was present. Pathologic findings, including microthrombi and epidermal necrosis were also consistent with the clinical diagnosis. Cutaneous vasculopathy associated with levamisole-adulterated cocaine, a recently described clinical entity, is characterized by a purpuric rash in a retiform pattern, with predilection for the ears, leukopenia, and ANCA positivity. This syndrome may be difficult to distinguish from a true

systemic vasculitis. Characteristic serologic abnormalities of cocaine - levamisole vasculopathy include high titer p-ANCA alone or both p-ANCA and c-ANCA positivity with anti-MPO and anti-PR3 antibodies. Low titer ANA, antiphospholipid antibodies and leukopenia are frequently present. The absence of end organ involvement with isolated skin manifestations, along with a typical serologic profile, differentiates cocaine – levamisole cutaneous vasculopathy from idiopathic systemic vasculitis.

Given the frequency of cocaine use in the US and the high rate of levamisole-adulteration, the diagnosis of cocaine – levamisole cutaneous vasculopathy syndrome should be suspected in any patient presenting with a purpuric rash, especially when the ear is involved, leukopenia, or positive ANCA test.

Acknowledgement: We wish to thank David Gemmel, PhD for critical review and support of the submitted manuscript and the Toxicology Laboratory, Colorado Department of Public Health and Environment.

References

1. Gross RL, Brucker J, Bahce-Altuntas A, Abadi MA, Lipoff J, Kotlyar D, Barland P, Putterman C. A novel cutaneous vasculitis syndrome induced by levamisole-contaminated cocaine. *Clin Rheumatol*. 2011;30(10):1385-1392.
2. Jenkins J, Babu K, Hsu-Hung E, Robinson-Bostom L, Kroumpouzou G. ANCA-positive necrotizing vasculitis and thrombotic vasculopathy induced by levamisole-adulterated cocaine: a distinctive clinicopathologic presentation. *J Am Acad Dermatol*. 2011;65(1):e14-16.
3. Menni S, Pistrutto G, Gianotti R, Ghio L, Edefonti A. Ear lobe bilateral necrosis by levamisole-induced occlusive vasculitis in a pediatric patient. *Pediatr Dermatol*. 1997;14(6):477-479.
4. Buchanan JA, Heard K, Burbach C, Wilson ML, Dart R. Prevalence of levamisole in urine toxicology screens positive for cocaine in an inner-city hospital. *JAMA*. 2011;305(16):1657-1658.
5. Lynch KL, Dominy SS, Graf J, Kral AH. Detection of levamisole exposure in cocaine users by liquid chromatography-tandem mass spectrometry. *J Anal Toxicol*. 2011;35(3):176-178.
6. Chang A, Osterloh J, Thomas J. Levamisole: a dangerous new cocaine adulterant. *Clin Pharmacol Ther*. 2010;88(3):408-411.
7. Rongioletti F, Ghio L, Ginevri F, Bleidl D, Rinaldi S, Edefonti A, Gambini C, Rizzoni G, Rebora A. Purpura of the ears: a distinctive vasculopathy with circulating autoantibodies

- complicating long-term treatment with levamisole in children. *Br J Dermatol.* 1999;140(5):948-951.
8. Farmer RW, Malhotra PS, Mays MP, Egger ME, Smith JW, Jortani SA, Spiller H, Bosse GM, Callen JP, Franklin GA. Necrotizing peripheral vasculitis/vasculopathy following the use of cocaine laced with levamisole. *J Burn Care Res.* 2012;33(1):e6-e11.
 9. Ching JA, Smith DJ, Jr. Levamisole-induced necrosis of skin, soft tissue, and bone: case report and review of literature. *J Burn Care Res.* 2012;33(1):e1-5.
 10. Geller L, Whang TB, Mercer SE, Phelps R. Retiform purpura: a new stigmata of illicit drug use? *Dermatol Online J.* 2011;17(2):7.
 11. Buchanan JA, Vogel JA, Eberhardt AM. Levamisole-induced occlusive necrotizing vasculitis of the ears after use of cocaine contaminated with levamisole. *J Med Toxicol.* 2011;7(1):83-84.
 12. Bradford M, Rosenberg B, Moreno J, Dumyati G. Bilateral necrosis of earlobes and cheeks: another complication of cocaine contaminated with levamisole. *Ann Intern Med.* 2010;152(11):758-759.
 13. Kouassi E, Caille G, Lery L, Lariviere L, Vezina M. Novel assay and pharmacokinetics of levamisole and p-hydroxylevamisole in human plasma and urine. *Biopharm Drug Dispos.* 1986;7(1):71-89.

14. Ullrich K, Koval R, Koval E, Bapoje S, Hirsh JM. Five consecutive cases of a cutaneous vasculopathy in users of levamisole-adulterated cocaine. *J Clin Rheumatol*. 2011;17(4):193-196.
15. Friedman DR, Wolfsthal SD. Cocaine-induced pseudovasculitis. *Mayo Clin Proc*. 2005;80(5):671-673.
16. McGrath MM, Isakova T, Rennke HG, Mottola AM, Laliberte KA, Niles JL. Contaminated cocaine and antineutrophil cytoplasmic antibody-associated disease. *Clin J Am Soc Nephrol*. 2011;6(12):2799-2805.
17. Walsh NM, Green PJ, Burlingame RW, Pasternak S, Hanly JG. Cocaine-related retiform purpura: evidence to incriminate the adulterant, levamisole. *J Cutan Pathol*. 2010;37(12):1212-1219.
18. Wiesner O, Russell KA, Lee AS, Jenne DE, Trimarchi M, Gregorini G, Specks U. Antineutrophil cytoplasmic antibodies reacting with human neutrophil elastase as a diagnostic marker for cocaine-induced midline destructive lesions but not autoimmune vasculitis. *Arthritis Rheum*. 2004;50(9):2954-2965.
19. Gao Y, Zhao MH. Review article: Drug-induced anti-neutrophil cytoplasmic antibody-associated vasculitis. *Nephrology (Carlton)*. 2009;14(1):33-41.

20. Thompson JS, Herbick JM, Klassen LW, Severson CD, Overlin VL, Blaschke JW, Silverman MA, Vogel CL. Studies on levamisole--induced agranulocytosis. *Blood*. 1980;56(3):388-396.
21. Buchanan JA, Oyer RJ, Patel NR, Jacquet GA, Bornikova L, Thienelt C, Shriver DA, Shockley LW, Wilson ML, Hurlbut KM, Lavonas EJ. A confirmed case of agranulocytosis after use of cocaine contaminated with levamisole. *J Med Toxicol*. 2010;6(2):160-164.
22. Mouzakis J, Somboonwit C, Lakshmi S, Rumbak M, Sinnott J, Cherpelis B, Keshishian J. Levamisole induced necrosis of the skin and neutropenia following intranasal cocaine use: a newly recognized syndrome. *J Drugs Dermatol*. 2011;10(10):1204-1207.
23. Centers for Disease C, Prevention. Agranulocytosis associated with cocaine use - four States, March 2008-November 2009. *Morb Mortal Wkly Rep*. 2009;58(49):1381-1385.
24. Zhu NY, Legatt DF, Turner AR. Agranulocytosis after consumption of cocaine adulterated with levamisole. *Ann Intern Med*. 2009;150(4):287-289.
25. Hanson KA, Heidrick ML. Immunomodulatory action of levamisole--II. Enhancement of concanavalin A response by levamisole is associated with an oxidation degradation product of levamisole formed during lymphocyte culture. *Int J Immunopharmacol*. 1991;13(6):669-676.

26. Czuchlewski DR, Brackney M, Ewers C, Manna J, Fekrazad MH, Martinez A, Nolte KB, Hjelle B, Rabinowitz I, Curtis BR, McFarland JG, Baumbach J, Foucar K. Clinicopathologic features of agranulocytosis in the setting of levamisole-tainted cocaine. *Am J Clin Pathol.* 2010;133(3):466-472.

Author Affiliations

Huy Tran, MD, PhD^{}; Debbie Tan, MD^{*}; Thomas P. Marnejon, DO^{*,†}*

^{}Internal Medicine Residency Program, Department of Medicine, St. Elizabeth Health Center, Youngstown, Ohio*

[†]Department of Medicine, Northeast Ohio Medical University, Rootstown, Ohio

Figures

Figure 1. Tender violaceous, non-blanching rash with areas of necrosis located on (a) the right earlobe and (b) right knee. There are scars on both sites from previous exposure to cocaine (open arrows)

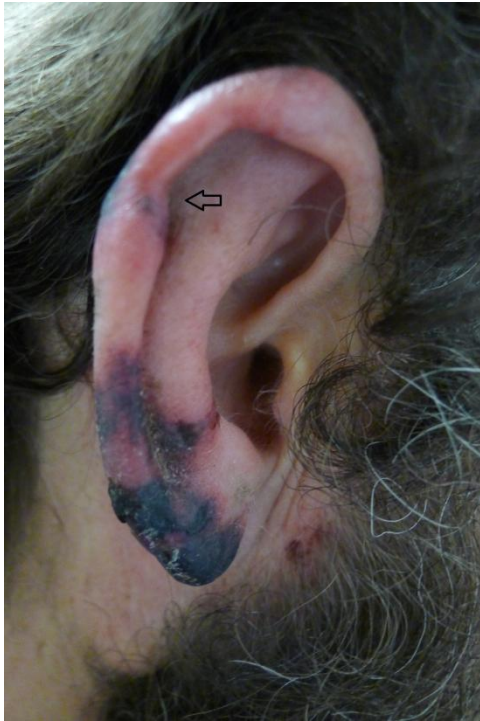

Figure 1a

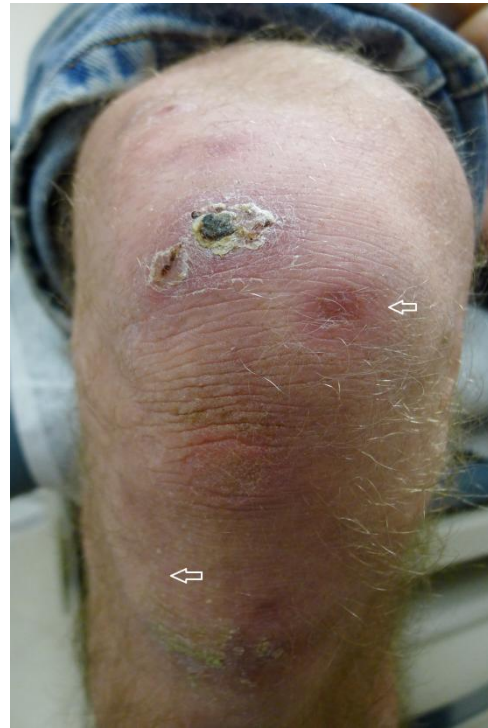

Figure 1b

Figure 2. Punch biopsy specimen of the skin which shows (a) epidermal necrosis (open arrow) with (b) intravascular fibrin thrombi of superficial and mid-dermal vessels (black arrows). Hematoxylin-eosin stain; magnification x40.

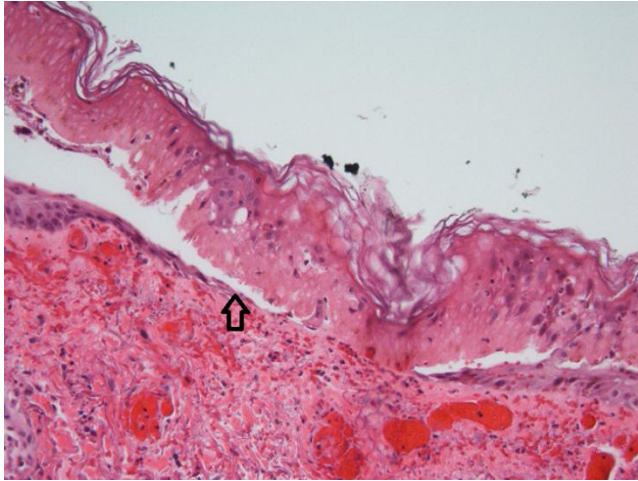


Figure 2a

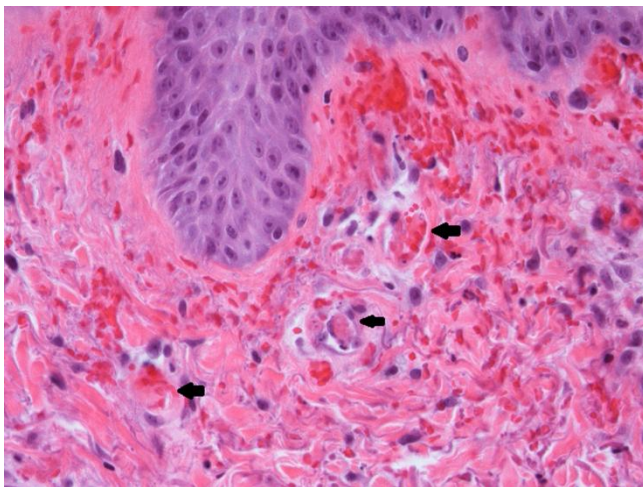


Figure 2b