

Superior Mesenteric Artery Syndrome in an Adolescent Female with Anorexia Nervosa

Lauren Bloomberg, MD; Matthew Hoscheit, MD; Steven Hendler, MD;
and Ayokunle T. Abegunde, MD

Superior mesenteric artery syndrome (SMAS) is a rare condition that develops from compression of the duodenum between the superior mesenteric artery (SMA) and abdominal aorta. SMAS is an atypical complication of restrictive eating disorders. The SMA is supported by adipose tissue to create an aortomesenteric angle that varies from 25-60 degrees. A reduction in adipose tissue causes narrowing of this angle, and SMAS develops when the aortomesenteric angle is narrow enough that it compresses the distal duodenum passing through. Patients present with small bowel obstructive symptoms. We report a severe case of SMAS in an adolescent female with anorexia nervosa who presented with acute and chronic symptoms of bowel obstruction. Awareness of the association between SMAS and restrictive eating disorders can help guide clinical decision-making and prevent delay of diagnosis and serious complications.

Keywords: Anorexia Nervosa; Duodenal Obstruction; Gastric Distension; Gastric Outlet Obstruction; Superior Mesenteric Artery Syndrome

Superior mesenteric artery syndrome (SMAS) is a rare condition that develops from compression of the duodenum between the superior mesenteric artery (SMA) and the abdominal aorta.¹ Loss of intraabdominal adipose tissue narrows the aortomesenteric angle, compressing the third portion of the duodenum passing through. Patients typically present with postprandial abdominal pain, nausea, vomiting, and weight loss. Though the most common etiology is rapid weight loss, other causes include scoliosis surgery, spinal trauma, and abdominal surgery. SMAS can also present as a rare complication of restrictive eating disorders. We report a case of SMAS in an adolescent, underweight female with significant weight loss and symptoms of bowel obstruction.

Case Report

A previously healthy female, aged 18 years, presented with

abdominal pain, distension, nausea, and vomiting. Symptoms began a year prior and followed meals. Her symptoms increased in severity until she could not tolerate oral intake. She reported an intentional 15-pound weight loss from 96 to 81 pounds over the previous 3 months, attributed to strenuous exercise and liquification of meals. On presentation, physical examination was remarkable for a thin female with a body mass index (BMI) of 15.5 kg/m² and sinus bradycardia of 40 beats per minute. Abdomen examination was remarkable for distension and diffuse tenderness to palpation with guarding. The remainder of physical examination was normal. Laboratory investigations were significant for hemoglobin of 11.1 g/dL (reference 12.9-17.3 g/dL), platelet count of 116,000/UL (reference 150,000-450,000/UL), magnesium of 1.7 mg/dL (reference range 1.7-2.2 mg/dL), phosphorus of 3.3 mg/dL (reference range 2.2-4.5 mg/dL), and albumin of 3.5 g/dL (reference range 3.4-5.4 g/dL).

Corresponding Author: Lauren Bloomberg, MD, Loyola University Chicago, Department of Internal Medicine, 2160 S. First Ave. Building 102, Room 7609, Maywood, IL 60153, Email: Lauren.Bloomberg@luhs.org

Received: May 23, 2022
Revised: August 18, 2022
Accepted: September 26, 2022

Disclosure: The authors declare no financial support or conflicts of interest related to this work. Informed patient consent was obtained for publication of case details.

doi:10.3121/cmr.2022.1768

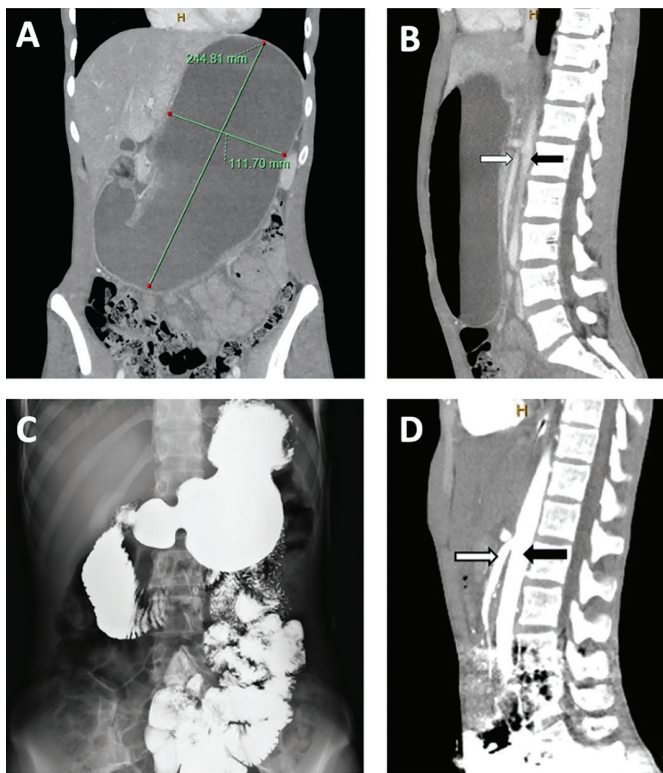


Figure 1. (A) Coronal abdomen and pelvic CT image demonstrating a markedly distended stomach measuring 24.48 cm by 11.70 cm with distended duodenal sweep into the mid abdomen with possibility of obstruction. (B) Sagittal abdomen and pelvic CT image demonstrating the SMA (white arrow) in relation to the aorta (black arrow) and the steep angle between them. (C) Upper gastrointestinal series revealing a caliber change involving the distal duodenum that is relatively narrower than the more proximal distended duodenum. There was delayed antegrade progression of contrast through this region of the duodenum. (D) Abdomen and pelvic CT with angiography demonstrating an acute angle between the SMA (white arrow) to the aorta (black arrow) with narrowing of the transverse duodenum, findings suspicious for superior mesenteric artery syndrome.

Abdominal and pelvic computed tomography (CT) revealed a markedly distended stomach and distended duodenal sweep into the middle abdomen (Figures A, B). Upper gastrointestinal series revealed narrowing of the distal duodenum with delayed progression of contrast through the third portion of the duodenum (Figure C). A nasogastric tube (NGT) was placed for decompression with non-bloody, bilious output. Abdominal and pelvic CT with angiography taken after NGT decompression revealed narrowed angulation of the SMA in relation to the aorta, with compression of the transverse duodenum, concerning for SMAS (Figure D). Small bowel, push enteroscopy was normal without evidence of gastric outlet obstruction, intrinsic masses, or narrowing. Given the

patient's symptoms, radiographic findings, and normal enteroscopy, she was diagnosed with SMAS.

Peripheral parenteral nutrition (PPN) was initiated. NGT with low intermittent suction was continued for 5 days with a total output of 4.5 liters. Oral intake was introduced and slowly advanced over 4 days to a regular diet. PPN was discontinued on day 8. She received a 5-day course of intravenous thiamine. Her symptoms significantly improved. She was evaluated by Child and Adolescent Psychiatry. Her strenuous exercise, restrictive diet, intentional weight loss, and anxiety met the criteria for anorexia nervosa. Inpatient nutritional rehabilitation was recommended, but the patient and her family elected for outpatient nutritional and psychiatric care. At subsequent outpatient follow ups, she was tolerating some oral intake, but was having difficulty with weight gain.

Discussion

The prevalence of SMAS is 0.013–0.3%, and the incidence is higher in females.² The most common etiologies involve rapid or severe weight loss.¹ However, weight loss is not necessary for the development of SMAS in the pediatric population.³ A pubertal growth spurt is a risk factor for SMAS. Acute and excessive ingestion of water and food can also trigger a manifestation of SMAS in adolescents whose visceral adipose tissue has already been depleted.³ The SMA originates from the anterior abdominal aorta at the level of L1 and is supported by adipose tissue. This normally creates an aortomesenteric angle of 25–60 degrees, with a distance of 10–28 mm between the SMA and aorta.¹ A reduction in adipose tissue narrows the aortomesenteric angle, compressing the third portion of the duodenum as it passes between the aorta and SMA.¹ Symptoms manifest when the angulation is <25 degrees or the aortomesenteric distance is <10 mm.¹ The classical presentation of SMAS includes postprandial abdominal pain, nausea, vomiting, and weight loss. Other symptoms may include early satiety and abdominal distension.⁴ These nonspecific symptoms often delay the diagnosis.

Our patient presented with severe weight loss with behaviors and symptoms concerning for a diagnosis of anorexia nervosa. Patients with anorexia nervosa and SMAS experience compounding weight loss effects. Diagnosing both diseases is challenging, as symptoms such as vomiting and reduced food intake can occur in either disorder. This presents as a challenge when delineating temporality. Typically, weight loss from anorexia nervosa can precipitate SMAS. However, SMAS developed from other etiologies can also simulate anorexia nervosa, and patients may develop food aversion as a palliative measure for obstructive symptoms.⁴

Concern for SMAS should be investigated with radiographic studies. Upper gastrointestinal series demonstrates obstruction of the distal duodenum, and abdominal CT with angiography reveals a narrowed aortomesenteric angle, a compressed distal

duodenum, and proximal duodenal and gastric distension.⁵ Small bowel enteroscopy should be performed to rule out intrinsic obstruction.¹ Enteroscopy is often normal but may reveal narrowing of the third portion of the duodenum due to extrinsic compression.

Treatment involves weight restoration to restore the abdominal fat pad, supporting the SMA into a non-obstructive position. If weight gain cannot be accomplished with oral intake, enteral feeding with a jejunal feeding tube is the preferred strategy, followed by parenteral nutrition.⁶ Patients with restrictive eating disorders should receive psychological evaluation and support.⁷ If conservative measures fail, surgical intervention with duodenojejunostomy may be considered.⁴ Strong's procedure and gastrojejunostomy have fallen out of favor due to high failure rate.⁴

In conclusion, we report a severe case of SMAS in an adolescent female with anorexia nervosa who presented with acute on chronic symptoms of bowel obstruction. Awareness of the association between SMAS and restrictive eating disorders can help guide clinical decision-making and prevent delay of diagnosis and serious complications.

References

1. Sinagra E, Raimondo D, Albano D, et al. Superior Mesenteric Artery Syndrome: Clinical, Endoscopic, and Radiological Findings. *Gastroenterol Res Pract.* 2018;2018:1937416. Published 2018 Aug 27. doi:10.1155/2018/1937416
2. Van Horne N, Jackson JP. Superior Mesenteric Artery Syndrome. In: *StatPearls.* Treasure Island (FL): StatPearls Publishing; July 18, 2022.
3. Okamoto T, Sato T, Sasaki Y. Superior mesenteric artery syndrome in a healthy active adolescent. *BMJ Case Rep.* 2019;12(8):e228758. doi:10.1136/bcr-2018-228758
4. Apostu RC, Chira L, Colcear D, et al. Wilkie's syndrome as a cause of anxiety-depressive disorder: A case report and review of literature. *World J Clin Cases.* 2022;10(5):1654-1666. doi:10.12998/wjcc.v10.i5.1654
5. Warncke ES, Gursahaney DL, Mascolo M, Dee E. Superior mesenteric artery syndrome: a radiographic review. *Abdom Radiol (NY).* 2019;44(9):3188-3194. doi:10.1007/s00261-019-02066-4
6. Haider A, Sharma M, Siddiq A. Superior Mesenteric Artery Syndrome: A Forgotten Cause of Duodenal Obstruction. *Cureus.* 2020;12(9):e10710. doi:10.7759/cureus.10710
7. Watters A, Gibson D, Dee E, Mascolo M, Mehler PS. Superior mesenteric artery syndrome in severe anorexia nervosa: A case series. *Clin Case Rep.* 2019;8(1):185-189. doi:10.1002/ccr3.2577

Author Affiliations

Lauren Bloomberg, MD;* Matthew Hoscheit, MD;† Steven Hendler, MD;† and Ayokunle T. Abegunde, MD†

*Department of Internal Medicine, Loyola University Medical Center, Maywood, IL, USA

†Division of Gastroenterology and Nutrition, Loyola University Medical Center, Maywood, IL, USA